

Cheiloscropy-Tool for Gender Determination in Forensic Odontology

Owais Gowhar¹, Tasneem S. Ain², Saima Sultan³

¹MDS Oral Pathology & Microbiology; Dept Of Dentistry, Govt. Dental Surgeon, J&K Health & Family Welfare Department.

²MDS Department Of Public Health Dentistry; Kothiwal Dental College & Research Centre, Moradabad, India

³MDS Department Of Pedodontics & Preventive Dentistry; Kothiwal Dental College & Research Centre, Moradabad, India.

Abstract

Background: Fast and secure identification processes in forensic odontology can be a very difficult process. Probably the most common techniques used are Dental, fingerprint and DNA comparisons. Since these techniques cannot always be used, it is necessary to apply different and less known techniques such as cheiloscropy. Due to its special features, lip groove can be used successfully in human identification. Cheiloscropy can pivotal role in identifying unknown persons both dead and alive.

Materials & methods: The present study was undertaken to ascertain the use of lip prints pattern in sex differentiation and evaluate differences in lip prints between males and females. Lip prints of 100 subjects, were obtained using lipstick and cello tape. The lip prints were analysed and classified according to Tsuchihashi classification. All the lip prints showed different patterns. Patterns of lip prints occurred in various combinations.

Result: The patterns were not similar between males and females. Type 1, 1(a) were mostly seen in females whereas type 4 and 5 were seen most commonly in Males.

Conclusion: For identification process cheiloscropy technique is still not widely used and is still in budding stage. Training programs and forensic dental education programs should be conducted in this regard. Oral pathologist can play a vital role as he is familiar with physiological and pathological features of oro-facial region.

I. Introduction

Cheiloscropy was first described by Fisher in 1902¹, however in 1930 Diou de Lille first used cheiloscropy in criminology² and in 1932 was acknowledged by Edmond Locard who was greatest criminologists³. In 1960 Santos recommended that the lip fissures could be divided into different groups (simple and compound)⁴. Renaud, in 1972, studied and confirmed the singularity of lip print⁵. Two years later, Suzuki and Tsuchihashi developed another study which resulted in a new classification for lip prints⁶.

Forensic odontology in India started in 1193 when Raja Jai Chand of Kanauj, was murdered by Muhammad Ghorri and was later identified by his false teeth. In 1991 former Prime Minister Mr. Rajiv Gandhi who was killed in suicide bomber was also identified from his dentition and December 2012 Delhi gang rape case was also solved by Dr Ashith B Acharya, the forensic odontologist with the help of bite mark analysis.⁷

Cheiloscropy is derived from Greek words cheilos meaning lips and e skopein to see and is the name given to the study of lip print.⁸ Lip prints are unique to one person, except in monozygotic twins and thus are important in identification⁹. Lip grooves are permanent and unchangeable like finger prints and palatal rugae.¹⁰ It is possible to identify lip patterns as early as the sixth week of in uterine life. From that moment on, lip groove patterns rarely change.⁸ In fact, only those pathologies that damage the lip like burns, seem to rule out cheiloscopic study⁵.

Under certain circumstances Dental records, fingerprint and DNA comparisons cannot always be used in the identification process¹¹. Fingerprints and bite marks are unique and used in convincing the court of law. Likewise, even lip prints patterns are considered to be unique to an individual and hence hold the potential for identification. Hence, lip prints patterns can lead us to important information and help in a person's identification¹². This study aims to ascertain the use of lip prints pattern in sex differentiation.

II. Materials And Methods

This study was carried out among the patients visiting various dental clinics in Srinagar, Kashmir. All patients were informed about purpose of study and all those who gave their consent were included in the study. 100 healthy subjects, (50 males and 50 females) individuals free of congenital abnormalities,

inflammation, trauma or orthodontic treatment were selected. Their ages ranging between 18-30 years. Individuals with known hypersensitivity to lipsticks were not included in the study.

In a single uniform stroke a dark colored lipstick was applied evenly on the vermilion border. After about two minutes, a lip impression was made on a strip of transparent cello tape on the glued portion, which was then stuck on to a white bond paper which served as a permanent record wherein the lip prints acquired were given codes after noting down the gender of the subjects. This positive impression was then visualized with different power magnifying lens. Following impression on paper lip prints consisting of furrows, lines and length were measured and recorded. To avoid bias while analyzing, the gender of the print was not revealed.

Classification proposed by Suzuki and Tsuchihashi in 1970 were used to classify the lip prints as it is commonly used lip print classification presently in literature. Advantages of using Tsuchihashi classification is that it has clear description and easy to understand & interpret.

Table 1: Suzuki & Tsuchihashi lip pattern classification	
Classification	Groove type
Type1	Complete vertical
Type1(a)	Incomplete vertical
Type2	Branched
Type3	Intersected
Type4	Reticular pattern
Type5	Irregular

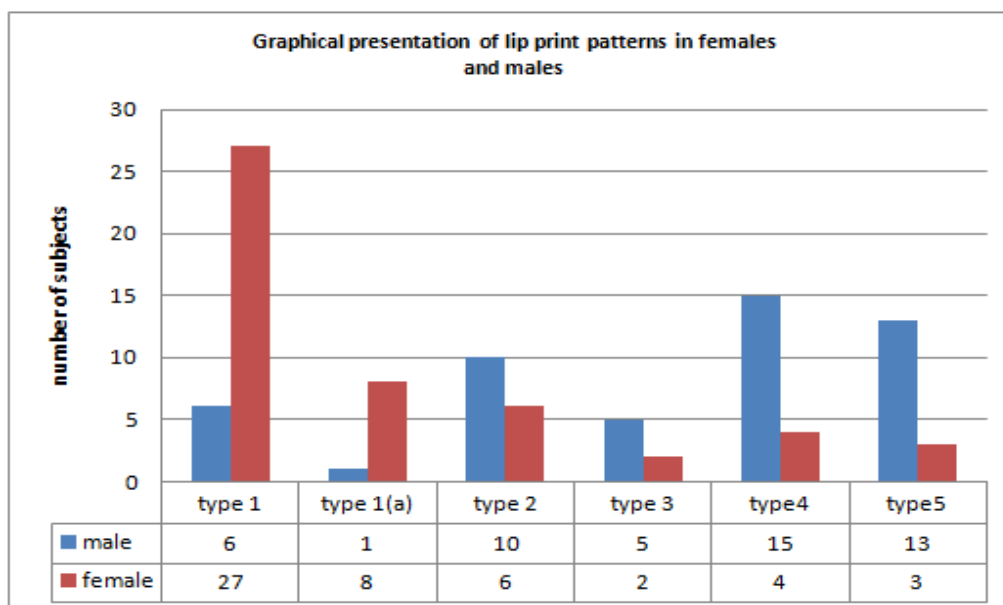
III. Results

Observations in our study were:

Out of 50 males type 1 was seen in 6males, type1(a) in 1 male, type2 in 10 males, type3 in 5 males, type4 in 15males and type5 in 13males.

Out of 50 females type1 was seen in 27 females, type1(a) in 8 females, type2 in 6 females, type 3 in 2 females, type 4 in 4 females and type 5 in 3 females.

In conclusion Type 1, 1(a) were mostly seen in females whereas type 4 and 5 were seen most commonly in Males & Forty two females were correctly recognized as females and forty six males were correctly identified as males on the basis of their lip prints.



IV. Discussion

Cheiloscopy is interesting mostly in identifying the living, since it can be the only way to link somebody to someone or to a specific location. However, although lip prints have previously been used in a court of law, its use is not consensual and some authors believe further evidence is needed to confirm their uniqueness².

The theory behind Identification of any living or dead individual is based on that all individuals are unique. Human identification being the mainstay of civilization has always been of supreme significance to society. Classification of individual persons into age, sex, race, height helps in narrowing the groups. Hence more unique the characteristic, the smaller the group becomes and more unique characteristics are prominent¹³.

Corner stone of forensic odontology is positive identification of living or deceased persons using the unique traits and characteristics of orofacial region¹⁴. Cheiloscopy have proven many a times as worthy weapon for personal identification. Lip print together with an persons structure of lines may constitute a source of circumstantial evidence¹⁵.

In the present study, we intended to explore out the variations in lip patterns of 100 subjects to determine whether the lip-prints can be used for sex determination from their pattern. Middle portion of lip is always visible in any trace that is the reason middle portion in the lip was taken into account although furrows are present, from one corner of the mouth to the other corner. In the past, many researchers such as Vahanwala and Parekh worked on lip prints for gender difference¹⁶.

It is extremely difficult to identify an individual in case where the lip lines are not clear, however individual identification of a human can also be made on characteristics such as scars. In these cases saliva, as a biological trace helps to determine the blood group in the ABO system. DNA typing also can be done from the lip print¹⁷. This process has not yet been explored much. When a lip print is found at the crime scene, the event character, people involved, gender, cosmetics used, behavior, occupation, and the pathological changes of lips can be concluded¹⁸.

At the crime scene items like photographs, cigarettes pieces, glasses, windows should be closely monitored and examined for search of appropriate evidences. Any trace of evidence can lead to huge useful information and which in turn can solve the case¹⁹. In our study lip prints were unique in every individual and did not matched with each other.

V. Conclusion

Past and present research in the field of cheiloscopy suggests that lip patterns can be used as a tool for identification of an individual and gender determination. More efforts must be done by reviewing in detail the various methods of classifying and analyzing lip patterns.

References

- [1]. Venkatesh R, David MP. Cheiloscopy: An aid for personal identification. *J Forensic Dent Sci.* 2011 Jul;3(2):67-70. doi: 10.4103/0975-1475.92147.
- [2]. Nitul Jain. *Textbook of Forensic Odontology.* Page 156. Jaypee brothers medical publishers.
- [3]. Dineshshankar J et al. Lip prints: Role in forensic odontology. *J Pharm Bioallied Sci.* 2013 Jun;5(Suppl 1):S95-7.
- [4]. Pankaj Mishra et al, *International Journal of Nursing Didactics*, 5 (6), June, 2015,
- [5]. Tim Peter et al. THE PHOENIX RISES – CHEILOSCOPY ?. *World Journal of Pharmaceutical Research.*2(6).2089-2098.
- [6]. Rachana V Prabhu, Ajit D Dinkar, Vishnudas Dinesh Prabhu. Collection of lip prints as a forensic evidence at the crime scene – an insight. *Journal of Oral Health Research*, Volume 1, Issue 4, December 2010.
- [7]. Narendra Nath Singh et al., Exploring Trends in Forensic Odontology. *Journal of Clinical and Diagnostic Research.* 2014 Dec, Vol-8(12): ZC28-ZC30.
- [8]. Anila Koneru et al. Comparison of lip prints in two different populations of India: Reflections based on a preliminary examination. *J Forensic Dent Sci.* 2013 Jan-Jun; 5(1): 11–15.
- [9]. Deepa Jatti, Pooja Rastogi. Digital Analysis of Lip Prints for Personal Identification: A Cross Sectional Study in South Indian Population. *J Indian Acad Forensic Med.* July-September 2015, Vol. 37, No. 3.
- [10]. Nagalaxmi et al. *The Open Dentistry Journal*, 2014, 8, 269-279.
- [11]. Anukool H. Pateria, Krushna Thakkar. Palatal rugae a stable landmark-A comparison between pre and post orthodontic patients. *International Journal Of Dental Clinics* 2011;3(4):9-12.
- [12]. Susmita Saxena, Preeti Sharma, Nitin Gupta. Experimental studies of forensic odontology to aid in the identification process. *J Forensic Dent Sci.* 2010 Jul-Dec; 2(2): 69–76.
- [13]. Sheetal P. Mhaske, Kiran Jagtap,,Rashmi Deshpande. Cheiloscopy- Tool For Forensic Identification. *IJDPM Vol (1) Issue (3) May – Aug 2013*
- [14]. Y. Josna Vinutha, V. Krishnapriya, G. Shilpa, D. Vasanti. Forensic dentistry: A Pedodontist’s perspective. *Journal of Medicine, Radiology, Pathology & Surgery* (2015), 1, 8–14.
- [15]. Nasreen Ishaq et al. Cheiloscopy. A Tool For Sex Determination. *Professional Med J* 2014;21(5): 883-887.
- [16]. Vahanwala SP, Parekh DK. Study of lip prints as an aid to forensic methodology. *J Indian Dent Assoc.* 2000;71:269–71.
- [17]. Prabhu RV, Dinkar AD, Prabhu VD, Rao PK. Cheiloscopy: Revisited. *J Forensic Dent Sci.*2012;4:4752
- [18]. Multani S, Thombre V, Thombre A, Surana P. Assessment of lip print patterns and its use for personal identification among the populations of Rajnandgaon, Chhattisgarh, India. *J Int Soc Prevent Communit Dent* 2014;4:170-4
- [19]. Gondivikar et al. sex determination using cheiloscopy. *journal of forensic dental sciences.*july-december;1(2);2009.